


The only anti-biofilm
silver dressing that supports
**CONTINUOUS DEBRIDEMENT
OF SLOUGH**



Supports continuous
debridement of slough^{5,6,13}



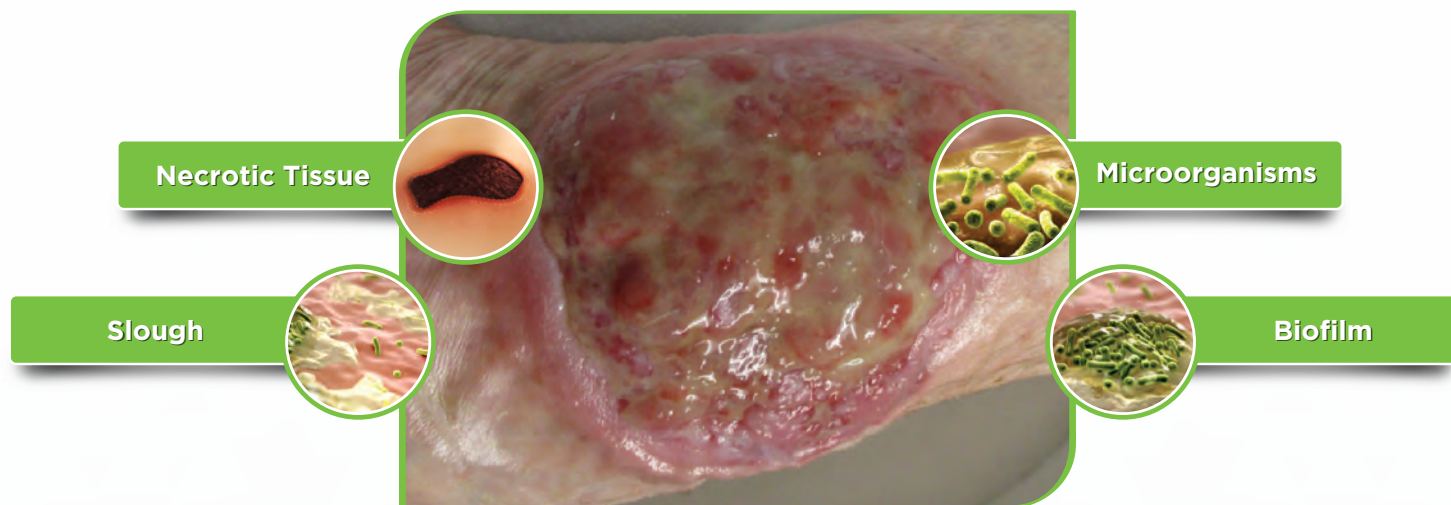
Destroys the biofilm and
prevent its reformation^{8,9,10,11}



Effectively fights against
signs of local infection^{6,13}

Debridement is a key step in wound bed preparation

A clean wound bed is achieved by removing visible and non-visible barriers.



Reference: Nair HKR, Balasubramaniam S, Frescos N et al (2024) Autolytic continuous debridement with a focus on biofilm management: Consensus document for the APAC region. London: Wounds International. Figure 2C-D.

Debridement is an important consideration in all wounds, especially when necrotic tissue, slough or other non-viable tissue is present in the wound bed.¹

With a range of debridement techniques available, it is important to select the method that is most appropriate and effective for the patient.¹

Debridement Methods

- Autolytic
- Surgical
- Biosurgical
- Sharp
- Enzymatic
- Ultrasonic
- Hydrosurgical
- Mechanical



- “Biofilm and associated debris **begins to reform 24 hours after debridement**”²
- “More frequent debridement was associated with improved healing. **Wounds that were debrided weekly or more frequently were over four times more likely to heal than wounds receiving debridement less often than weekly**”³
- “Best Practice for wound debridement proposes a new approach referred to as integral debridement, which is defined as **‘the combined use of different but complementary methods of debridement on the same wound’**.”⁴

Continuous debridement of slough is the solution

1

EFFECTIVE^{5,6}

Promotes healing and maximises debridement effect by continuously removing slough, wound debris and mitigates reformation of microbial colonies

2

EASY TO ACCESS

Accessible to all caregivers in order to harness the benefits of debridement throughout the continuum of care

3


EASY TO USE & COMFORTABLE^{5,6}

Easy to use by healthcare providers and well tolerated by patients

UrgoClean Ag

Polyabsorbent fibres (Magnet fibers technology)

- Support the continuous debridement of slough
- Fibrin, microorganisms and wound residue attach to the fibres to continuously clean the wound bed^{5,6}
- Fibres form a gel to promote moist wound healing^{7,12}
- Maintains a clean wound bed, optimizing silver efficacy in the wound^{6,13}



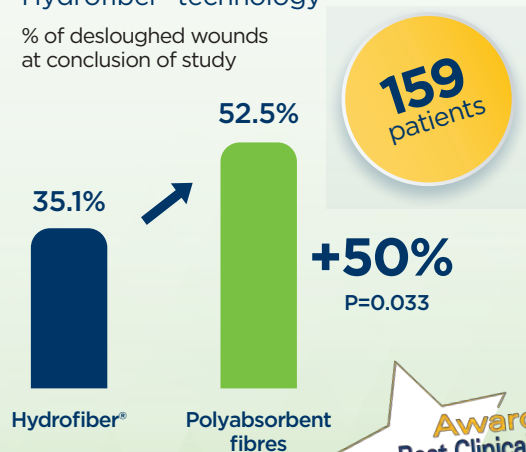
Antimicrobial (TLC-Ag)

- Fast, broad-spectrum, antimicrobial-barrier efficacy⁸
- Together with the magnet fibers technology, it destroys the biofilm and prevent its reformation^{8,9,10,11}
- TLC-Ag matrix promotes healing and atraumatic, pain-free removal^{6,12}

Proven Efficacy


In an RCT, Polyabsorbent fibres (Magnet fibers technology) showed **+50% greater debridement of slough** compared to Hydrofiber[®] technology⁵

% of desloughed wounds at conclusion of study



The Largest Observational Study ever published for a silver dressing¹³

- ✓ 2,270 patients including 77 under the age of 18 years old
- ✓ After only 3 weeks, 90.6% of the wounds treated **demonstrated improvement** of the healing process
- ✓ UrgoClean Ag effectively **reduced exudate level by 63.8%**
- ✓ **No intolerance to the dressing** was documented

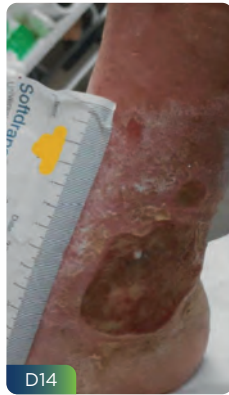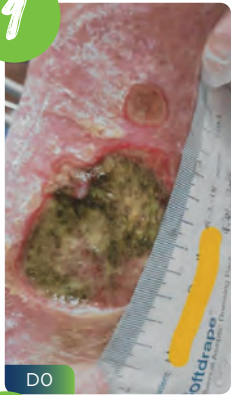


2,270 patients



Clinical cases of UrgoClean Ag

1

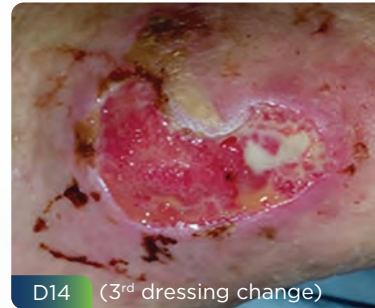
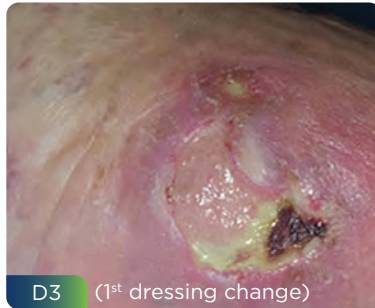
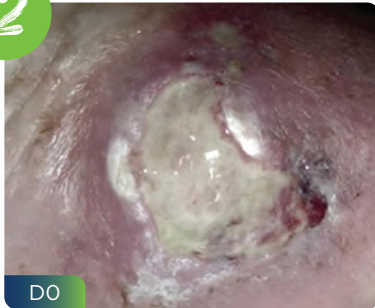
- 80 year-old female patient
- Extensive venous leg ulcers on bilateral lower legs
- She had three wounds for several months and had been ignoring them
- Wounds with 100% slough and were odorous with thick green exudate present
- Severe pain reported and difficulties to sleep and walk
- Deep red and excoriated peri-wound skin
- Treatment initiated with **UrgoClean Ag**

RESULTS

- 40% granulation tissue
- Dramatic reduction of pain and exudate
- Improvement of peri-wound skin
- Wound size & depth reduction with new epithelial tissue present

2



- 87 year-old female patient with a traumatic wound to the left ankle, 4-weeks duration showing overt signs of local infection (erythema)
- Previous treatment: non-adhesive foam dressings
- Treatment changes for **UrgoClean Ag**

RESULTS

- Reduction of the signs of local infection
- 90% granulation tissue
- Improvement of peri-wound skin

How to use UrgoClean Ag

Step 1: Clean the wound following current cleansing protocol. **Do not moisten** UrgoClean Ag

Step 2: Pat the wound dry with a sterile gauze

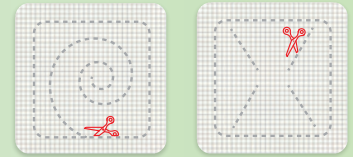
Step 3: When appropriate, maintain the current debridement protocol as needed

Step 4: Cut as needed, ensuring there is enough to cover the periwound and allow the dressing to make contact with the wound bed

Step 5: Remove the protective films and apply the brown, diamond-pattern side of the dressing to the wound

Step 6: Cover with a secondary dressing appropriate for wound type, level of exudate, and the location

Step 7: Replace the dressing every 1 to 2 days during the wound desloughing phase, then as often as required (up to 7 days) according to the clinical assessment



Code	Description	Units
100490	UrgoClean Ag - 6 cm x 6 cm	10 each/box
100491	UrgoClean Ag - 10 cm x 10 cm	10 each/box
100492	UrgoClean Ag - 15 cm x 20 cm	5 each/box



Can be cut



Can be used under compression



Can be used with other dressings



Safe for use on periwound skin



Haemostatic⁷

References: 1. Nair HKR, Balasubramaniam S, Frescos N et al (2024) Autolytic continuous debridement with a focus on biofilm management: Consensus document for the APAC region. London: Wounds International. 2. Schultz, G. et al (2017), Consensus guidelines for the identification and treatment of biofilms in chronic nonhealing wounds. Wound Rep and Reg, 25: 744-757. Wounds International. 3. European Pressure Ulcer Advisory Panel, National Pressure Injury Advisory Panel and Pan Pacific Pressure Injury Alliance. Prevention and Treatment of Pressure Ulcers/Injuries: Clinical Practice Guideline. The International Guideline. Emily Haesler(Ed.), EPUAP/NPIAP/PPPIA.2019. 4. Dieter O Mayer et al (2024) JWC International Consensus Document – Best Practice for wound debridement. Journal of wound care. VOL.33, NO.6, Sup 6. 5. Meaume S., Dissemond J., et al. Evaluation of two fibrous wound dressings for the management of leg ulcers: Results of a European randomised controlled trial (Earth RCT). 2014. Journal of Wound Care 23(3): 105-106, 108-111, 114-116. 6. Dalac S., Sigal L., Addala A., et al Clinical evaluation of a dressing with poly absorbent fibres and a silver matrix for managing chronic wounds at risk of infection: a non comparative trial. September 2016, J Wound Care, Vol 25, No 9, 531-538. 7. In vitro data - report n°177804, March 2014. 8. Desroche N, Drobot C, Janod P, et al. Antibacterial properties and reduction of MRSA biofilm with a dressing combining polyabsorbent fibres and a silver matrix. J Wound Care 2016; 25: 577-584. 9. Percival SL, et al., Slough and biofilm: removal of barriers to wound healing by desloughing. J Wound Care. 2015 Nov;24(11): 498, 500-3, 506-10. 10. Bartoszewicz M et al. Efficacy of UrgoClean Ag dressing against biofilms formed by chronic wounds pathogens. Leczenie Ran 2018;15(2): 45-50. 11. Bartoszewicz M et al. In vitro suitability of a lipocolloid dressing containing silver ions for the eradication of mixed Pseudomonas aeruginosa and Staphylococcus aureus biofilms formed under different culture conditions. Forum Zakazen 2022; 13(4): 111-119. 12. Internal report Laboratoires Urgo n°RE/UR/2021-563/SOL. 13. Dissemond J., et al. Use of a TLC-Ag dressing on 2270 patients with wounds at risk or with signs of local infection: an observational study. Journal of Wound Care, Vol 29, N°3, March 2020.

Refer to patient leaflet for more information.

Urgo Medical (Australia) Pty Limited
Level 2, 100 Cubitt Street Cremorne, Victoria 3121
Tel +61 (0) 39114 2222 | Visit urgomedical.com.au

*/** all trademarks are the property of their respective owners. © 2025 Urgo Medical Australia Pty Ltd.

